



5-2011

# Evaluating Dimensional Accuracy and Reliability of "Stitched" Small Field of View (SSFOV) Cone Beam Computed Tomography (CBCT) Datasets for Use in Proprietary Dental Implant Guided Surgery Software

Nicholas Luke Egbert

*University of Tennessee Health Science Center*

Follow this and additional works at: <https://dc.uthsc.edu/dissertations>



Part of the [Prosthodontics and Prosthodontology Commons](#)

## Recommended Citation

Egbert, Nicholas Luke, "Evaluating Dimensional Accuracy and Reliability of "Stitched" Small Field of View (SSFOV) Cone Beam Computed Tomography (CBCT) Datasets for Use in Proprietary Dental Implant Guided Surgery Software" (2011). *Theses and Dissertations (ETD)*. Paper 68. <http://dx.doi.org/10.21007/etd.cghs.2011.0080>.

This Thesis is brought to you for free and open access by the College of Graduate Health Sciences at UTHSC Digital Commons. It has been accepted for inclusion in Theses and Dissertations (ETD) by an authorized administrator of UTHSC Digital Commons. For more information, please contact [jwelch30@uthsc.edu](mailto:jwelch30@uthsc.edu).

---

# Evaluating Dimensional Accuracy and Reliability of "Stitched" Small Field of View (SSFOV) Cone Beam Computed Tomography (CBCT) Datasets for Use in Proprietary Dental Implant Guided Surgery Software

**Document Type**

Thesis

**Degree Name**

Master of Dental Science (MDS)

**Program**

Prosthodontics

**Research Advisor**

David R. Cagna, D.M.D., M.S.

**Committee**

Robert L. Brandt, D.D.S, M.S. Jeffrey H. Brooks, D.M.D. Vinay Jain, B.D.S, M.S., M.D.S. Mark Scarbecz, Ph.D.

**DOI**

10.21007/etd.cghs.2011.0080

**Evaluating Dimensional Accuracy and Reliability of “Stitched” Small Field of View  
(SSFOV) Cone Beam Computed Tomography (CBCT) Datasets for Use in  
Proprietary Dental Implant Guided Surgery Software**

A Thesis  
Presented for  
The Graduate Studies Council  
The University of Tennessee  
Health Science Center

In Partial Fulfillment  
Of the Requirements for the Degree  
Master of Dental Science  
From The University of Tennessee

By  
Nicholas Luke Egbert D.D.S.  
May 2011

Copyright © 2011 by Nicholas Luke Egbert D.D.S.  
All rights reserved.

## **ACKNOWLEDGEMENTS**

I would like to express my sincere gratitude to everyone who has helped me pursue a Master of Dental Science in Prosthodontics. I am grateful to my mentor Dr. David Cagna, for his example, persistence and encouragement. I would also like to thank my remaining committee members, Drs. Mark Scarbecz, Robert Brandt, Vinay Jain and Jeffrey Brooks for their advice and experience. I would also like to acknowledge Kodak Dental systems for donating the hardware and software to the University of Tennessee Health Science Center College of Dentistry for clinical and research use. Lastly, I would also like to thank American College of Prosthodontics Education Foundation for providing us a research fellowship.

## ABSTRACT

**Background:** Recently a “stitched” small field of view (SSFOV) cone beam computed tomography (CBCT) extraoral imaging system (Kodak 9000D, Carestream Health Inc, Kodak Dental Systems, Marne-la-Vallee, France) has been released. The benefits of the 3D stitching module of stitched SFOV CBCT may include: broader range of applications, affordability, flexibility, safety optimizing radiation dose and improved workflow. With the reduced effective dose of radiation and cost to both the patient and clinician, this superior imaging modality becomes more accessible to the community, potentially elevating the standard of care. Currently, stitched data sets are restricted to diagnostic data gathering only. To date, no study has addressed the use of stitched SFOV CBCT data sets for import and use in the fabrication of image-guided CAD/CAM dental implant surgical stents. In comparison to conventional implant surgery, image-guided surgery provides safe, less-invasive treatment and superior planning ability and accuracy for the clinician.

**Objective:** The purpose of this study was to evaluate the dimensional accuracy and reliability of stitched SFOV CBCT reconstructed images for use in the fabrication of surgical dental implant guides.

**Methods:** Three 1.5 x 1.5 mm gutta percha points were fixated on the inferior border of a human mandible serving as control reference points. An additional ten, 1.5 x 1.5 mm gutta percha points, representing fiduciary markers of a proposed radiographic template, were then scattered on the buccal and lingual cortex at the level of the proposed complete denture flange. The distances between reference points and fiduciary markers were measured with digital calipers by providing an anatomic linear dimension (ALD). The mandible was scanned, images reconstructed and “stitched” using manufacturer’s imaging software (Kodak 9000, Carestream Health Inc, Kodak Dental Systems, Marne-la-Vallee, France). The same measurements were accomplished within the CBCT software using the provided measuring tools and statistically evaluated for dimensional stability.

**Results:** In comparing the control (ALD) to the CBCT measurements, the mean difference between the ALD and SSFOV CBCT was found to be 0.34 mm with a 95% confidence interval of +0.24 to +0.44 and a mean standard deviation of 0.30. No systematic bias between the difference of the observations was evident. Thus, each measurement appeared to be as good as the other. The differences between the control and CBCT were acceptable within the defined parameters of this study.

**Conclusions:** Considering human error, this difference is considered clinically acceptable but should be accounted for when reading CBCT for diagnostic and or planning purposes. Proven accuracy of stitched SFOV CBCT data sets may allow image-guided implant surgical stents to be fabricated from such data sets.

## TABLE OF CONTENTS

<b>CHAPTER 1: INTRODUCTION AND BACKGROUND.....</b>	<b>1</b>
<b>CHAPTER 2: REVIEW OF LITERATURE .....</b>	<b>3</b>
<b>CHAPTER 3: MATERIALS AND METHODS .....</b>	<b>5</b>
<b>CHAPTER 4: RESULTS .....</b>	<b>10</b>
<b>CHAPTER 5: DISCUSSION .....</b>	<b>12</b>
<b>CHAPTER 6: CONCLUSIONS .....</b>	<b>14</b>
<b>LIST OF REFERENCES .....</b>	<b>15</b>
<b>APPENDIX: SUMMARY OF MEASUREMENTS.....</b>	<b>21</b>
<b>VITA.....</b>	<b>25</b>

## CHAPTER 1: INTRODUCTION AND BACKGROUND

The dental profession has entered a new age of radiographic diagnostic imaging (Guttenberg 2008). Subsequent to the reduction of effective dose radiation (Ludlow *et al.* 2003, 2006, 2008; Brooks 2008; Okano *et al.* 2008; Roberts *et al.* 2009) cost, size and image acquisition time, the use of Cone Beam Computed Tomography (CBCT) has increased significantly this past decade in the field of dentistry (Mozzo *et al.* 1998; Arai *et al.* 1999; Danforth *et al.* 2003; Sukovic 2003; Miles 2008; White and Pharoah 2008; Zoller and Neugebauer 2008). Conventional radiography produces distorted, magnified, superimposed grey-scale images that compromise visualization rendering pre-surgical diagnostic measurements subjective (Serman 1989). CBCT produces 3D virtual reconstructed and multi-planar reconstructed images including: cross-sectional (bucco-lingual), axial, coronal, sagittal and panoramic views (Scarfe and Farman 2008). Unparalleled submillimeter spatial resolution and geometric accuracy provides clinician's with solutions to diagnostic and surgical tasks improving the prognosis of future treatment (Sukovic 2003; Miles 2008).

Medical grade CT was initially used for dental applications in the late 1980's (Schwarz *et al.* 1989) and early 1990's (Garg and Vicari 1995). Many clinical applications of dental CBCT are found in the literature (Scarfe *et al.* 2006). Clinical applications include but are not limited to the following: complex 3<sup>rd</sup> molar surgery (Danforth *et al.* 2003; Susarla and Dodson 2007; Tantanapornkul *et al.* 2007; Flygare and Ohman 2008); minor oral surgery and orthognathic surgery (Nakagawa *et al.* 2002; Troulis *et al.* 2002; Alves *et al.* 2007; Caloss *et al.* 2007); orthodontic treatment, diagnosis and treatment planning (Maki *et al.* 2003; Caprioglio *et al.* 2007; Hechler 2008; Stratemann *et al.* 2008); assistance in complicated endodontic diagnosis and treatment (Patel *et al.* 2007, 2009; Patel 2009); visualizing and diagnosing temporomandibular joint disorders (Hilgers *et al.* 2005; Lewis *et al.* 2008) and sleep apnea (Strauss and Burgoyne 2008).

In a review of the literature by BouSerhal *et al.* (2002) researchers concluded many situations demand the use of cross-sectional imaging techniques for optimal preoperative planning of implant placement. Bone density and anatomic vital structures such as the inferior alveolar nerve and maxillary sinus may also be visualized, measured and anticipated prior to surgery (Aranyarachkul *et al.* 2005; Greenstein and Tarnow 2006; Lee *et al.* 2007). CBCT information may also be used to plan and construct stereolithographic and or CAD/CAM surgical stents increasing the accuracy of planned implant placement. If appropriate, the surgery may be performed flapless and may allow delivery of an immediate prefabricated prosthesis (Kraut 1998, Sarment *et al.* 2003; Perel and Triplett 2004; Balshi *et al.* 2006; Guerrero *et al.* 2006; Nikzad and Azari 2008; Jung *et al.* 2009; Valente *et al.* 2009; Ganeles, 2010; Ganz, 2010; Wilson, 2010). Using all available virtual tools, true restoratively driven implant dentistry can be accomplished via image-guided surgery, ultimately benefiting patients (Ganz 2008, 2010).

All aforementioned applications of CBCT technology assume the scan and



subsequent reconstruction are dimensionally accurate and interpreted correctly by the clinician. Many studies are found in the literature verifying the dimensional accuracy of CBCT imaging; most of which using osteologic landmarks on dry human skulls as reference points for measurement (Lascalea *et al.* 2004; Hilgers *et al.* 2005; Morishi *et al.* 2007; Lagrave *et al.* 2008; Loubele *et al.* 2008; Periago *et al.* 2008; Berco *et al.* 2009; Hassan *et al.* 2009; Moriera *et al.* 2009).

## CHAPTER 2: REVIEW OF LITERATURE

Kobayashi and colleagues first (2004) evaluated the accuracy of images produced by a prototype limited cone-beam computed tomography (LCBCT) in comparison to spiral CT (SCT). The vertical distance from a reference point to the alveolar ridge was measured by caliper on 5 sliced cadaver mandibles, and the measurement values obtained from the CT images were accurately reproduced with a <2.2% error. More recently Loubele and colleagues (2008) placed gutta percha reference points on both sides of the alveolar ridge in a formalin-fixed human maxilla at known distances. Images were produced using CBCT (Accuitomo 3D; Morita, Kyoto, Japan) and MSCT (4-slice Somatom VolumeZoom and 16-slice Somatom Sensation 16; Siemens, Erlangen, Germany) and measured. Both CBCT and MSCT yielded submillimeter accuracy for linear measurements on an *ex vivo* specimen.

Few studies demonstrate inconsistencies in the dimensional accuracy of CBCT imaging and its associated software reconstruction. Lascala and colleagues (2004) made 13 measurements on 8 dry skulls with digital calipers which served as a control. CBCT images were obtained (NewTom 9000; Quantitative Radiology, Verona, Italy) measured on proprietary software and compared to the control measurements. It was found the CBCT underestimated the measurements as compared to the control near the skull base. Inconsistencies in the accuracy of the reconstructed DICOM files by a proprietary software program were reported by Periago and colleagues in the literature (2008). Control measurements were made with digital calipers of 23 cephalometric landmarks on 23 different human skulls. The authors concluded many linear measurements between cephalometric landmarks on 3D volumetric surface renderings obtained using Dolphin 3D software generated from CBCT datasets may be statistically, significantly different from anatomic dimensions.

Recent studies have been published regarding proper head positioning during scan acquisition. Berco *et al.* (2009) and Hassan *et al.* (2009) insist skull orientation during CBCT scanning does not affect the accuracy or the reliability of the measurements.

The Kodak 9000D (Carestream Health Inc, Kodak Dental Systems, Marne-la-Vallee, France) 3D stitching program is a new 3D acquisition mode that automatically combines two or three localized volumes to construct a larger, composite 3D image that is needed for a wider region of examination (80mm by 37mm). The exams are shot one after the other (2 or 3 acquisitions). The unit is automatically directed to the multiple areas of the jaw that need to be imaged. When all the exams are completed, the software combines the volumes and reconstructs them into one composite image. The benefits of the 3D stitching module are: broader range of applications, affordability, flexibility and safety optimizing radiation dose and improved workflow.

In an unpublished study Garladinne-Nethi and colleagues (2008) compared the accuracy and reliability of linear horizontal measurements made on reformatted panoramic images from stitched small field of view (SFOV), large field of view (FOV)

CBCT datasets and conventional digital panoramic images to the anatomical truth. They found linear measurements on panoramic images reconstructed from stitched small FOV images to be reliable and accurate. This study did not include vertical nor angular measurements whose accuracy is imperative to image-guided surgical treatment.

Kopp and Ottl (2010) most recently published in the Journal of Dentomaxillofacial Radiology attempting to verify the dimensional stability of the Kodak 9000 using endodontic files in select teeth. Distances were measured between reproducible points and found to be acceptable (vertical distances varied between 0.212 and 0.409 mm). The authors conclude: “further evaluation...for subsequent splint fabrication may yield promising results” (Kopp and Ottl 2010, 516).

Currently, Kodak (Dental Systems Group, Carestream Health Inc, Kodak Dental Systems, Marne-la-Vallee, France) approved the use of stitched SFOV reconstructed data sets for the fabrication of implant surgical guides (Dual Scan 9000 Protocol, 2010). However, no scientific study has proven or disproven its application for surgical guides. The purpose of this study is to evaluate the accuracy and reliability of linear and angular measurements of gutt percha reference points and fiduciary markers, similar to those used in radiographic templates, with the Kodak 9000 CBCT stitching software. This may validate the use of stitched volumetric data sets in fabrication of stereolithographic and CAD/CAM surgical guides.

### CHAPTER 3: MATERIALS AND METHODS

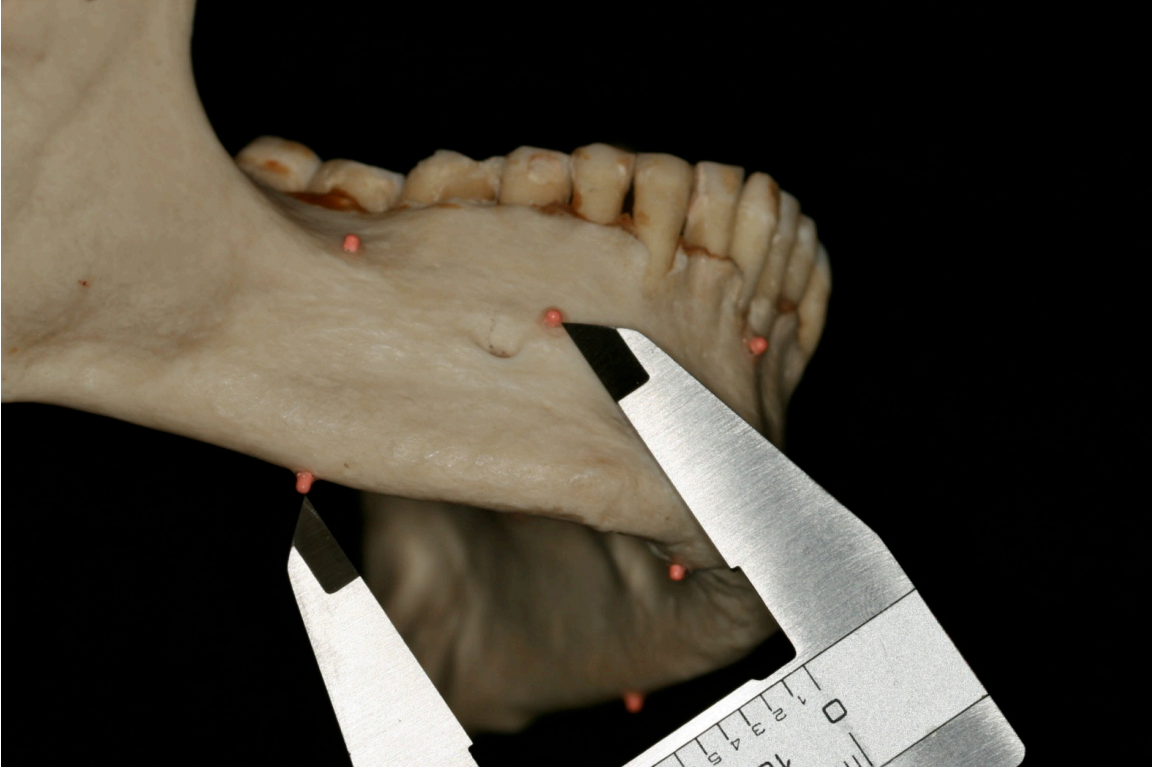A single dentate dry human mandible, free of outstanding defects, was acquired for the study. Three 1.5 mm by 1.5 mm gutta percha (Henry Schein, Melville NY) reference points were then placed along the mid-crest of the inferior border of the mandible fixed with cyanoacrylate. These three points coincided with proposed “center” of the three localized spherical volumes recorded by the Kodak 9000D (Dental Systems Group, Carestream Health Inc, Kodak Dental Systems, Marne-la-Vallee, France). The first gutta percha reference point was placed on the lower right inferior border of the mandible inferior to the 1<sup>st</sup> molar #30. The second reference point was placed on the inferior border, mid-symphysis. The third reference point was fixated on the inferior border of the mandible inferior to the 1<sup>st</sup> molar #19. This positioning allowed for stable, accessible landmarks from which to measure with both digital calipers and in the reconstructed SSFOV CBCT renderings.

An additional ten, staggered, 1.5 mm x 1.5 mm gutta percha (Henry Schein, Melville NY) markers were placed in similar fashion at bone level. These markers represented fiduciary markers of a radiographic template preparatory for scanning and import into a proprietary guided surgery application. Markers were placed on each side of the mandible, five buccal and five lingual. This ensured 1 reference point and at least three fiduciary markers appear in each of the three localized spherical volumes. Using a myostatic outline, care was taken to place markers within the proper superio-inferior position coinciding with the proposed flanges of a radiographic template (Figure 3-1).

Control measurements were made using precision sliding digital calipers (General Tools, New York, NY) from the inferior, external center of reference point to reference point and each reference point to external center surface of all 10 fiduciary markers. Inter-reference point measurements were also made.

Control measurements using precision sliding digital calipers were recorded beginning with the lower right reference point. This point was designated reference point A for simplicity. The reference point found mid-symphysis was designated reference point B. The reference point in the lower left quadrant was designated reference point C. The fiduciary markers were labeled 1-10 beginning with the buccal lower right quadrant numbering sequentially, in counter-clockwise fashion, all buccal markers then lingual. Measurements were taken three times on three different days by the primary researcher. Data was compiled using a Microsoft Excel spreadsheet. The mean of the three measurements became the “anatomic linear dimension” (ALD) (Figure 3-1).

The mandible was then positioned on a calibration table in the Kodak 9000D (Carestream Health Inc, Kodak Dental Systems, Marne-la-Vallee, France). A 1.5 inch foam pad with a 0.5 mm thickness Biocryl (Great Lakes Orthodontics, Tonawanda, NY) separated the mandible from the calibration table and the foam as to not distort the visualization of the reference points by the calibration table or foam once scanned and reconstructed. The mandible was positioned with the aid of laser lights with the inferior

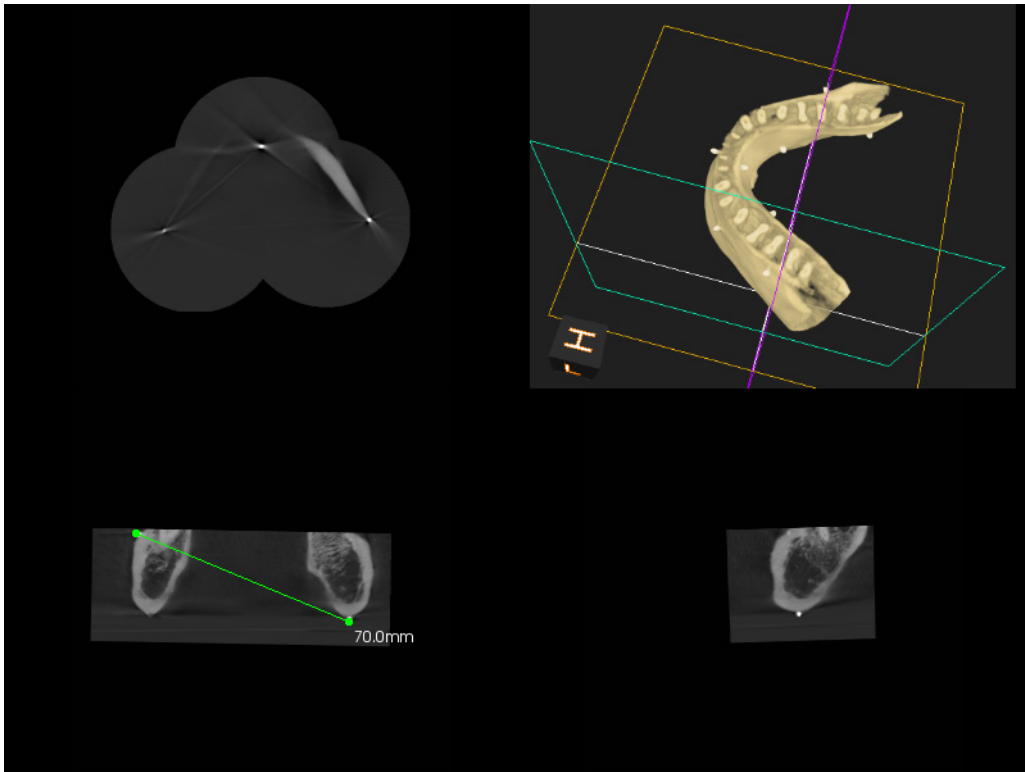


**Figure 3-1.** Control Measurement (ALD).

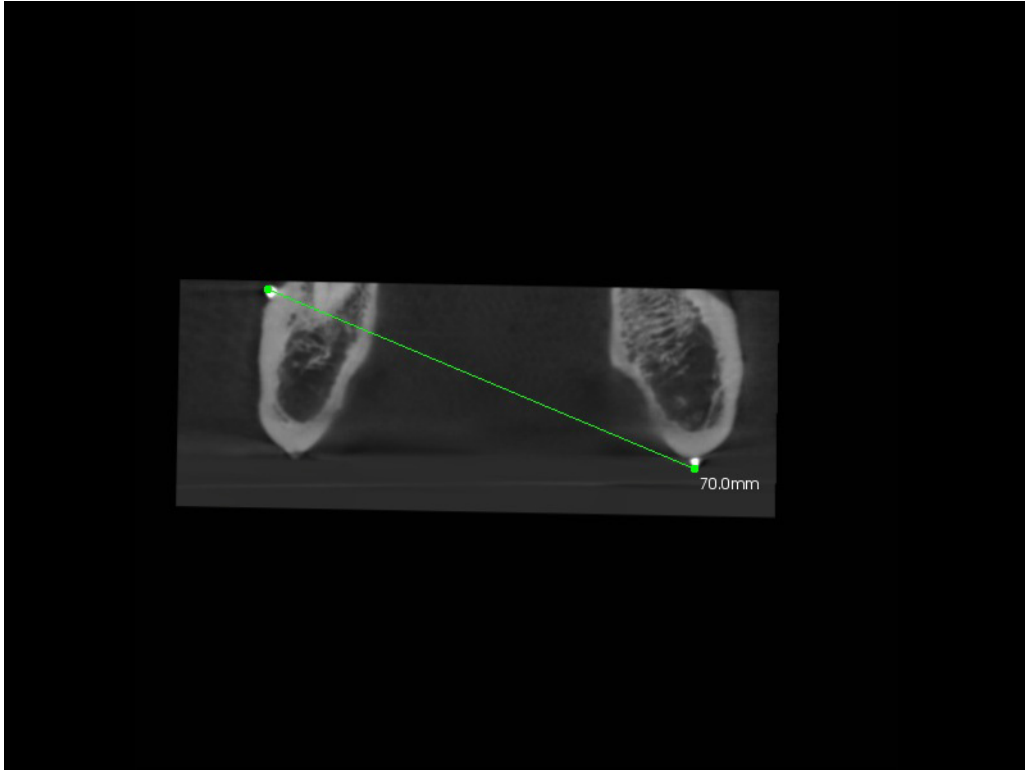
border of the mandible parallel with the horizontal plane and the mid-sagittal plane aligned perpendicular to the horizontal plane. This altered positioning, inferior border versus the occlusal plane being parallel to the horizontal plane, allows for the capture of the entire mandible and all associated reference points despite the SFOV (37mm) and will not affect scanning accuracy per Berco *et al.* (2009) and Hassan *et al.* (2009). The scan was performed with the following reduced exposure settings: mA 6, KvP 80, 0.018 s and 0.2 Voxels (resolution), accounting for the lack of soft tissue density.

The scan was taken with care as to not move the mandible from its' position while scanning all three volumes. Images were acquired with a charged coupled device (CCD) sensor (Kodak RVG 6100). The raw DICOM data was stitched into a composite 3D rendering using the latest version of the Kodak 9000 proprietary software (KDIS v. 6.11.6.2 and 3D module v. 2.1). Multiplanar reconstruction (sagittal, para-sagittal, axial and coronal) slices were correctly manipulated and used to visualize and measure the linear and or angular distances from the three reference markers to each of the ten fiduciary markers with the software measuring tool. The images were viewed on a 19 inch monitor in default resolution (Dell, 1600 x 1200 pixels; 60 Hz; 200cdm, 300:1 contrast; 25 ms reaction time). The points and markers were visually located and marked with a 1000 dpi mouse (Dell).

Similar to the control, measurements were made from the inferior, center of the reference points to the center, external surface of the fiduciary markers. Care was taken to correctly adjust each slice in multi-planar reconstruction (MPR) view, identifying the most superficial aspect of each marker possible mimicking the control measurements made with the calipers (Figures 3-2 and 3-3). Measurements were made three times on three different days and logged into the spread-sheet. The mean was calculated for each measurement and considered the stitched small field of view CBCT dimension (SSFOV CBCT).



**Figure 3-2.** Reconstructed Stitched Small Field of View.



**Figure 3-3.** Measurement in Frontal Plane of Reconstructed SSFOV.



## CHAPTER 4: RESULTS

Intra-operator control groups (ALD) and study group measurements (SSFOV CBCT) were tabulated for each of the three series of measurements taken for each groups (Appendix). The mean ALD was calculated for each of the three measurements (Table 4-1). The mean SSFOV CBCT was also calculated for each of the three measurements to allow analysis between the two groups (Table 4-2).

The means of the two groups were compared and the difference was determined between the groups by the mean SSFOV CBCT measurements from the control group (ALD). The overall mean difference between the control (ALD) and SSFOV CBCT measurements was 0.34 mm. The mean standard deviation between the two groups was 0.30 with a 95% confidence interval of  $\pm 0.102$  (0.24 to 0.44).

Intra-operator, control measurements made on the skull with digital calipers (ALD) were analyzed and found to be statistically significantly different. This is attributed to the small 0.10 mm standard deviation in differences between measurements. The mean difference between control measurements was -0.01 mm 95% confidence interval bound of -0.04 to -0.03 (Table 4-1) with a standard deviation of 0.10. Sharp digital calipers and sharp gutta percha appoints facilitated accurate measurement of fiducial markers and reference points. Although statistically significantly different, mean differences of hundredths of a millimeter are not clinically relevant.

Differences in intra-operator CBCT digital measurements, were also found to be statistically, significantly different. The average mean difference between intra-operator CBCT measurements was -0.08 mm with a 95% confidence interval of -0.12 to -0.03 (Table 4-2). The statistical significance of these measurements is also due to the small 0.14 mm standard deviation in differences between measurements. This phenomenon may be explained due to controlled, predictable detection of the center of each gutta-percha marker on the mandible by manipulating multiple sub-millimeter planes viewed in the SSFOV CBCT software. The points were detected as a result of their radiopacity in each plane. Multiplanar views were manipulated until a slight, "pin-point" radiopacity was detected facilitating finding the center of each point. Despite the statistical analysis, a mean difference of -0.08 with a standard deviation of 0.14 mm is not clinically significant.

In comparing the control (ALD) to the CBCT measurements, the mean difference between the ALD and SSFOV CBCT was found to be 0.34 mm with a 95% confidence interval of +0.24 to +0.44 and a mean standard deviation of 0.30 (Table 4-3). No systematic bias between the difference of the observations. Thus, each measurement appeared to be as good as the other. The differences between the control and CBCT were acceptable within the defined parameters of this study.

**Table 4-1.** Statistical Analysis of Intra-Operator ALD (Control) Measurements.

<b>ALD (CONTROL)</b>	<b><math>\Delta</math> (obs1-obs2)</b>	<b><math>\Delta</math> (obs1-obs3)</b>	<b><math>\Delta</math> (obs2-obs3)</b>	<b>Mean</b>
Overall Mean	-0.01	-0.01	0.00	-0.01
Overall Standard Deviation	0.18	0.15	0.14	0.10
95% Confidence Interval	(-0.07 to -0.06)	(-0.06 to 0.04)	(-0.05 to -0.04)	(-0.04 to 0.03)

Notes: ALD = Anatomic Linear Dimension,  $\Delta$  = Change between Measurements, obs = Observation Group.

**Table 4-2.** Statistical Analysis of Intra-Operator SSFOV CBCT Measurements.

<b>SSFOV CBCT</b>	<b><math>\Delta</math> (obs1-obs2)</b>	<b><math>\Delta</math> (obs1-obs3)</b>	<b><math>\Delta</math> (obs2-obs3)</b>	<b>Mean</b>
Overall Mean	-0.11	-0.12	-0.01	-0.08
Overall Standard Deviation	0.21	0.21	0.19	0.14
95% Confidence Interval	(-0.18 to -0.04)	(-0.19 to -0.04)	(-0.07 to 0.06)	(-0.12 to -0.03)

Notes: SSFOV = Stitched Small Field of View, CBCT = Cone Beam Computed Tomography,  $\Delta$  = Change between Measurements, obs = Observation Group.

**Table 4-3.** Statistical Analysis between Groups.

<b>Mean Difference</b>	<b>(ALD - SSFOV CBCT)</b>
Overall Mean Difference	0.34
Overall Standard Deviation	0.3
95% Confidence Interval	(0.24 to 0.44)

Notes: ALD = Anatomic Linear Dimension, SSFOV = Stitched Small Field of View CBCT = Cone Beam Computed Tomography.

## CHAPTER 5: DISCUSSION

A mean difference of 0.34 mm between the ALD and SSFOV CBCT measurements was found. As found in previous studies, it appears as though the CBCT data, or the interpretation thereof, may be dimensionally underestimated (Table 4-3).

Few studies demonstrate inconsistencies in the dimensional accuracy of CBCT imaging and its associated software reconstruction. Lascaia and colleagues (2004) made 13 measurements on 8 dry skulls with digital calipers which served as a control. CBCT images were obtained (NewTom 9000; Quantitative Radiology, Verona, Italy) measured on proprietary software and compared to the control measurements. It was found the CBCT underestimated the measurements as compared to the control near the skull base. Inconsistencies in the accuracy of the reconstructed DICOM files by a proprietary software program were reported by Periago and colleagues in the literature (2008). Control measurements were made with digital calipers of 23 cephalometric landmarks on 23 different human skulls. The authors concluded many linear measurements between cephalometric landmarks on 3D volumetric surface renderings obtained using Dolphin 3D software generated from CBCT datasets may be statistically, significantly different from anatomic dimensions. Whether or not these measurements are clinically significant is a matter of defining the parameters for clinical significance.

A 1mm margin of error was considered the threshold for accuracy in this study. A 1mm margin of error was chosen due to its common application and use in nearly all clinical dental procedures. Parameters for restorative dental procedures are evaluated and executed in millimeter scale. To ensure successful treatment it is proposed the root canal space be properly instrumented and obturated within 1 mm of the root's apex. Probe depths are used to diagnose and treat the periodontium are used and visualized in a millimeter scale. More pertinent to this study, a 2mm "safety" zone near vital structures has been suggested when surgically planning and placing dental implants near vital structures (Greenstein and Tarnow 2006). This suggestion was based on conventional radiography with its' inherent distortions mentioned previously. Discrepancies greater than 1mm, with additional statistical margins of error, may encroach on these clinically accepted safety parameters.

Despite SSFOV CBCT's superior image accuracy, due to the operators visual and tactile limitations, it may not be prudent to assume one can approximate vital structures during surgical procedures with closer proximity than previously recommended in the literature.

According the results of this study, the likelihood of measurement discrepancies are likely to occur when using both analog measuring instruments (*i.e.*, calipers, probes etc.) and with digital SSFOV CBCT measurements. This increases the need for the accurate conversion of SSFOV CBCT images to CAD/CAM guides allowing for the safest surgery possible.

As noted previously, both the ALD and SSFOV CBCT differences were statistically significantly different yet clinically insignificant due to the sub-millimeter resolution of the measurements. This difference is beyond the resolution of the human eye and hand as noted above with the control measurements.

Measurement differences between control (AT) and stitched SFOV CBCT reconstructed images may allow image-guided implant surgical stents to be fabricated from such data sets. As recommended by Kopp and Ottl (2010) verification of the stitched rendering by measuring between two reference points in the scan and on the template may be judicious.

In dual scan, guided surgical protocols, landmarks such as definitive reference points or notches simply made with a round bur mid-symphysis and near the posterior borders of the radiographic template outside the positional osteotomy sites, would provide reference points in each of the three fields of view. These markers may be verified in the reconstructed image with digital measurements in the multi-planar views of the CBCT image. If the measurements are coincidental the operator should feel confident of the SSFOV. If significant discrepancies in measurement occur, the scan or stitched volumes may be inaccurate and cause the subsequent guide to be inaccurate. If this occurs, the guided surgery may be aborted.

These reference landmarks should also be measured and analyzed for potential dimensional changes during the fabrication of the subsequent implant surgical stent. cross-arch on radiographic template incorporating template landmarks for measurement verification of the subsequent guide. If a discrepancy is found the accuracy of the guide must be assumed inaccurate. Any inaccuracies found at this stage may be at the mercy of the guide fabrication process. Further studies may be needed to verify the accuracy of the guide fabrication process with the supplied DICOM files.

## CHAPTER 6: CONCLUSIONS

In conclusion, the stitched composite 3D images appear accurate and reliable for diagnostic purposes within the operator's physical limitations and parameters defined in this study. Clinically insignificant differences found between the control measurements and those of the stitched data sets may be taken into consideration when diagnosing and treatment planning both surgical and non-surgical dental procedures.

This minuscule difference may allow image-guided implant surgical stents to be fabricated from such data sets but not without difficulty. Comparing measurements between landmarks in each of the three spherical columns of the radiographic template with the corresponding markers seen in the reconstructed stitched SSFOV CBCT scan, and once again in the surgical guide, may alert the clinician of an inaccurate image reconstruction or template fabrication. If a discrepancy is found, the guide must be assumed inaccurate. Any inaccuracies found at this stage may be at the mercy of the guide fabrication process. Further studies may be needed to verify the accuracy of the guide fabrication process with the supplied DICOM files.

Despite stitched SFOV CBCT's superior image accuracy, due to the operators' visual and tactile limitations, it may not be prudent to assume one can approximate vital structures during surgical procedures with closer proximity than previously recommended in the literature.

## LIST OF REFERENCES

- Alves PV, Bolognese AM, Zhao L. Three-dimensional computerized orthognathic surgical treatment planning. *Clin Plast Surg.* 2007 Jul;34(3):427-36.
- Arai Y, Tammisalo E, Iwai K, Hashimoto K, Shinoda K. Development of a compact computed tomographic apparatus for dental use. *Dentomaxillofac Radiol.* 1999 Jul;28(4):245-8.
- Aranyarachkul P, Caruso J, Gantes B, Schulz E, Riggs M, Dus I, Yamada JM, Crigger M. Bone density assessments of dental implant sites: 2. Quantitative cone-beam computerized tomography. *Int J Oral Maxillofac Implants.* 2005 May-Jun;20(3):416-24.
- Balshi SF, Wolfinger GJ, Balshi TJ. Surgical planning and prosthesis construction using computer technology and medical imaging for immediate loading of implants in the pterygomaxillary region. *Int J Periodontics Restorative Dent.* 2006 Jun;26(3):239-47.
- Berco M, Rigali PH Jr, Miner RM, DeLuca S, Anderson NK, Will LA. Accuracy and reliability of linear cephalometric measurements from cone-beam computed tomography scans of a dry human skull. *Am J Orthod Dentofacial Orthop.* 2009 Jul;136(1):17.e1-9; discussion 17-8.
- BouSerhal C, Jacobs R, Quirynen M, van Steenberghe D. Imaging technique selection for the preoperative planning of oral implants: A review of the literature. *Clin Implant Dent Relat Res.* 2002;4(3):156-72.
- Brooks, SL. Radiation doses of common dental radiographic examinations: A review. *Acta Stomatol Croat.* 2008;42(3):207-17.
- Brown AA, Scarfe WC, Scheets JP, Silveira AM, Farman AG. Linear accuracy of cone beam CT derived images. *Angle Orthod.* 2009 Jan;79(1):150-7.
- Caloss R, Atkins K, Stella JP. Three-dimensional imaging for virtual assessment and treatment simulation in orthognathic surgery. *Oral Maxillofac Surg Clin North Am.* 2007 Aug;19(3):287-309.
- Caprioglio A, Siani L, Caprioglio C. Guided eruption of palatally impacted canines through combined use of 3-dimensional computerized tomography scans and the easy cuspid device. *World J Orthod.* 2007 Summer;8(2):109-21.
- Danforth RA, Peck J, Hall P. Cone beam volume tomography: An imaging option for diagnosis of complex mandibular third molar anatomical relationships. *J Calif Dent Assoc.* 2003 Nov;31(11):847-52.

- Flygare L, Ohman A. Preoperative imaging procedures for lower wisdom teeth removal. *Clin Oral Investig*. 2008 Dec;12(4):291-302.
- Ganeles J., Grossberg, D. Complications related to immediately loaded dental implants. In: *Dental Implant Complications*. pp 71-99. John Wiley and Sons Ltd. West Sussex, UK. 2010.
- Ganz SD. Computer-aided design/computer-aided manufacturing applications using CT and cone beam CT scanning technology. *Dent Clin North Am*. 2008 Oct;52(4):777-808, vii.
- Ganz SD. Implant complications associated with two- and three-dimensional diagnostic imaging technologies. In: *Dental Implant Complications*. pp 71-99. John Wiley and Sons Ltd. West Sussex, UK. 2010.
- Garg AK, Vicari A. Radiographic modalities for diagnosis and treatment planning in implant dentistry. *Implant Soc*. 1995;5(5):7-11.
- Greenstein G, Tarnow D. The mental foramen and nerve: Clinical and anatomical factors related to dental implant placement: A literature review. *J Periodontol*. 2006 Dec;77(12):1933-43.
- Guerrero ME, Jacobs R, Loubele M, Schutyser F, Suetens P, van Steenberghe D. State-of-the-art on cone beam CT imaging for preoperative planning of implant placement. *Clin Oral Investig*. 2006 Mar;10(1):1-7.
- Guttenberg SA. Oral and maxillofacial pathology in three dimensions. *Dent Clin North Am*. 2008 Oct;52(4):843-73, viii.
- Hassan B, van der Stelt P, Sanderink G. Accuracy of three-dimensional measurements obtained from cone beam computed tomography surface-rendered images for cephalometric analysis: Influence of patient scanning position. *Eur J Orthod*. 2009 Apr;31(2):129-34.
- Hechler SL. Cone-beam CT: Applications in orthodontics. *Dent Clin North Am*. 2008 Oct;52(4):809-23, vii.
- Hilgers ML, Scarfe WC, Scheetz JP, Farman AG. Accuracy of linear temporomandibular joint measurements with cone beam computed tomography and digital cephalometric radiography. *Am J Orthod Dentofacial Orthop*. 2005 Dec;128(6):803-11.
- Jung RE, Schneider D, Ganeles J, Wismeijer D, Zwahlen M, Hämmerle CH, Tahmaseb A. Computer technology applications in surgical implant dentistry: A systematic review. *Int J Oral Maxillofac Implants*. 2009;24 (Suppl):92-109.

- Kopp S, Ottl P. Dimensional stability in composite cone beam computed tomography. *Dentomaxillofac Radiol.* 2010; (39):512-16.
- Kobayashi K, Shimoda S, Nakagawa Y, Yamamoto A. Accuracy in measurement of distance using limited cone-beam computerized tomography. *Int J Oral Maxillofac Implants.* 2004 Mar-Apr;19(2):228-31.
- Kraut RA. Interactive CT diagnostics, planning and preparation for dental implants. *Implant Dent.* 1998;7(1):19-25.
- Lagravre MO, Carey J, Toogood RW, Major PW. Three-dimensional accuracy of measurements made with software on cone-beam computed tomography images. *Am J Orthod Dentofacial Orthop.* 2008 Jul;134(1):112-6.
- Lascalea CA, Panella J, Marques MM. Analysis of the accuracy of linear measurements obtained by cone beam computed tomography (CBCT-NewTom). *Dentomaxillofac Radiol.* 2004 Sep;33(5):291-4.
- Lee S, Gantes B, Riggs M, Crigger M. Bone density assessments of dental implant sites: 3. Bone quality evaluation during osteotomy and implant placement. *Int J Oral Maxillofac Implants.* 2007 Mar-Apr;22(2):208-12.
- Lewis EL, Dolwick MF, Abramowicz S, Reeder SL. Contemporary imaging of the temporomandibular joint. *Dent Clin North Am.* 2008 Oct;52(4):875-90, viii. Review.
- Loubele M, Van Assche N, Carpentier K, Maes F, Jacobs R, van Steenberghe D, Suetens P. Comparative localized linear accuracy of small-field cone-beam CT and multislice CT for alveolar bone measurements. *Oral Surg Oral Med Oral Pathol Oral Radiol Endod.* 2008 Apr;105(4):512-8.
- Ludlow JB, Davies-Ludlow LE, Brooks SL. Dosimetry of two extraoral direct digital imaging devices: NewTom cone beam CT and Orthophos Plus DS panoramic unit. *Dentomaxillofac Radiol.* 2003 Jul;32(4):229-34.
- Ludlow JB, Davies-Ludlow LE, Brooks SL, Howerton WB. Dosimetry of 3 CBCT devices for oral and maxillofacial radiology: CB Mercuray, NewTom 3G and i-CAT. *Dentomaxillofac Radiol.* 2006 Jul;35(4):219-26.
- Ludlow JB, Ivanovic M. Comparative dosimetry of dental CBCT devices and 64-slice CT for oral and maxillofacial radiology. *Oral Surg Oral Med Oral Pathol Oral Radiol Endod.* 2008 Jul;106(1):106-14.
- Mah J, Enciso R, Jorgensen M. Management of impacted cuspids using 3-D volumetric imaging. *J Calif Dent Assoc.* 2003 Nov;31(11):835-41.



- Maki K, Inou N, Takanishi A, Miller AJ. Computer-assisted simulations in orthodontic diagnosis and the application of a new cone beam X-ray computed tomography. *Orthod Craniofac Res.* 2003;6 (Suppl 1):95-101; discussion 179-82.
- Miles, DA. Cone beam volumetric imaging in clinical practice. In: *Color Atlas of Cone Beam Volumetric Imaging for Dental Applications.* pp1-14. Quintessence Publishing Co Inc. Hanover Park, IL. 2008.
- Miles DA. The future of dental and maxillofacial imaging. *Dent Clin North Am.* 2008 Oct;52(4):917-28, viii.
- Misch KA, Yi ES, Sarment DP. Accuracy of cone beam computed tomography for periodontal defect measurements. *J Periodontol.* 2006 Jul;77(7):1261-6.
- Moshiri M, Scarfe WC, Hilgers ML, Scheetz JP, Silveira AM, Farman AG. Accuracy of linear measurements from imaging plate and lateral cephalometric images derived from cone-beam computed tomography. *Am J Orthod Dentofacial Orthop.* 2007 Oct;132(4):550-60.
- Moreira CR, Sales MA, Lopes PM, Cavalcanti MG. Assessment of linear and angular measurements on three-dimensional cone-beam computed tomographic images. *Oral Surg Oral Med Oral Pathol Oral Radiol Endod.* 2009 Sep;108(3):430-6.
- Mozzo P, Procacci C, Tacconi A, Martini PT, Andreis IA. A new volumetric CT machine for dental imaging based on the cone-beam technique: Preliminary results. *Eur Radiol.* 1998;8(9):1558-64.
- Nakagawa Y, Kobayashi K, Ishii H, Mishima A, Ishii H, Asada K, Ishibashi K. Preoperative application of limited cone beam computerized tomography as an assessment tool before minor oral surgery. *Int J Oral Maxillofac Surg.* 2002 Jun;31(3):322-6.
- Nikzad S, Azari A. A novel stereolithographic surgical guide template for planning treatment involving a mandibular dental implant. *J Oral Maxillofac Surg.* 2008 Jul;66(7):1446-54.
- Okano T, Harata Y, Sugihara Y, Sakaino R, Tsuchida R, Iwai K, Seki K, Araki K. Absorbed and effective doses from cone beam volumetric imaging for implant planning. *Dentomaxillofac Radiol.* 2009 Feb;38(2):79-85.
- Parel SM, Triplett RG. Interactive imaging for implant planning, placement, and prosthesis construction. *J Oral Maxillofac Surg.* 2004 Sep;62(9 Suppl 2):41-7.
- Patel S. New dimensions in endodontic imaging: Part 2. Cone beam computed tomography. *Int Endod J.* 2009 Jun;42(6):463-75.

- Patel S, Dawood A, Whaites E, Pitt Ford T. New dimensions in endodontic imaging: Part 1. Conventional and alternative radiographic systems. *Int Endod J.* 2009 Jun;42(6):447-62.
- Patel S, Dawood A, Pitt Ford T, Whaites E. The potential applications of cone beam computed tomography in the management of endodontic problems. *Int Endod J.* 2007 Oct;40(10):818-30.
- Periago DR, Scarfe WC, Moshiri M, Scheetz JP, Silveira AM, Farman AG. Linear accuracy and reliability of cone beam CT derived 3-dimensional images constructed using an orthodontic volumetric rendering program. *Angle Orthod.* 2008 May;78(3):387-95.
- Roberts JA, Drage NA, Davies J, Thomas DW. Effective dose from cone beam CT examinations in dentistry. *Br J Radiol.* 2009 Jan;82(973):35-40.
- Rustemeyer P, Streubühr U, Suttmoeller J. Low-dose dental computed tomography: Significant dose reduction without loss of image quality. *Acta Radiol.* 2004 Dec;45(8):847-53.
- Sarment DP, Sukovic P, Clinthorne N. Accuracy of implant placement with a stereolithographic surgical guide. *Int J Oral Maxillofac Implants.* 2003 Jul-Aug;18(4):571-7.
- Scarfe WC, Farman AG. What is cone-beam CT and how does it work? *Dent Clin North Am.* 2008 Oct;52(4):707-30, v.
- Scarfe WC, Farman AG, Sukovic P. Clinical applications of cone-beam computed tomography in dental practice. *J Can Dent Assoc.* 2006 Feb;72(1):75-80.
- Schorn C, Visser H, Hermann KP, Alamo L, Funke M, Grabbe E. Dental CT: Image quality and radiation exposure in relation to scan parameters. *Rofo.* 1999 Feb;170(2):137-44.
- Schwarz MS, Rothman SL, Chafetz N, Rhodes M. Computed tomography in dental implantation surgery. *Dent Clin North Am.* 1989 Oct;33(4):555-97.
- Serman NJ. Pitfalls of panoramic radiology in implant surgery. *Ann Dent.* 1989;48:13-6.
- Stratemann SA, Huang JC, Maki K, Miller AJ, Hatcher DC. Comparison of cone beam computed tomography imaging with physical measures. *Dentomaxillofac Radiol.* 2008 Feb;37(2):80-93.
- Strauss RA, Burgoyne CC. Diagnostic imaging and sleep medicine. *Dent Clin North Am.* 2008 Oct;52(4):891-915, viii. Review.

- Sukovic P. Cone beam computed tomography in craniofacial imaging. *Orthod Craniofac Res.* 2003;6 (Suppl 1):31-6; discussion 179-82.
- Susarla SM, Dodson TB. Preoperative computed tomography imaging in the management of impacted mandibular third molars. *J Oral Maxillofac Surg.* 2007 Jan;65(1):83-8.
- Tantanapornkul W, Okouchi K, Fujiwara Y, Yamashiro M, Maruoka Y, Ohbayashi N, Kurabayashi T. A comparative study of cone-beam computed tomography and conventional panoramic radiography in assessing the topographic relationship between the mandibular canal and impacted third molars. *Oral Surg Oral Med Oral Pathol Oral Radiol Endod.* 2007 Feb;103(2):253-9.
- Thomas SL. Application of cone-beam CT in the office setting. *Dent Clin North Am.* 2008 Oct;52(4):753-9, vi.
- Troulis MJ, Everett P, Seldin EB, Kikinis R, Kaban LB. Development of a three-dimensional treatment planning system based on computed tomographic data. *Int J Oral Maxillofac Surg.* 2002 Aug;31(4):349-57.
- Tyndall DA, Rathore S. Cone-beam CT diagnostic applications: Caries, periodontal bone assessment, and endodontic applications. *Dent Clin North Am.* 2008 Oct;52(4):825-41, vii.
- Valente F, Schirolli G, Sbrenna A. Accuracy of computer-aided oral implant surgery: A clinical and radiographic study. *Int J Oral Maxillofac Implants.* 2009 Mar-Apr;24(2):234-42.
- White SC, Pharoah MJ. The evolution and application of dental maxillofacial imaging modalities. *Dent Clin North Am.* 2008 Oct;52(4):689-705, v.
- Wilson Jr, TG. Complications associated with flapless surgery. In: *Dental Implant Complications.* pp 71-99. John Wiley and Sons Ltd. West Sussex, UK. 2010.
- Zoller JE, Neugebauer. Fundamentals of cone-beam volumetric imaging technology. In: *Cone-Beam Volumetric Imaging in Dental, Oral and Maxillofacial Medicine. Fundamentals, Diagnostics and Treatment Planning.* Quintessence Publishing Co Inc. Hanover Park, IL. 2008.

## APPENDIX: SUMMARY OF MEASUREMENTS

**Table A-1.** Summary of Control (ALD) Measurements.

<b>ALD Control</b>	<b>C1</b>	<b>C2</b>	<b>C3</b>	<b><math>\Delta 1v2</math></b>	<b><math>\Delta 1v3</math></b>	<b><math>\Delta 2v3</math></b>	<b><math>\Delta Avg</math></b>	<b>Mean</b>	<b>SD</b>
A-B	39.48	39.57	39.55	-0.09	-0.07	0.02	-0.05	39.53	0.04
B-C	39.67	39.75	39.61	-0.08	0.06	0.14	0.04	39.68	0.06
A-C	62.88	62.78	62.81	0.10	0.07	-0.03	0.05	62.82	0.04
A-1	26.6	26.32	26.49	0.28	0.11	-0.17	0.07	26.47	0.12
A-2	30.62	30.46	30.64	0.16	-0.02	-0.18	-0.01	30.57	0.08
A-3	51.4	51.43	51.57	-0.03	-0.17	-0.14	-0.11	51.47	0.07
A-4	60.77	60.94	60.89	-0.17	-0.12	0.05	-0.08	60.87	0.07
A-5	70.22	70.01	70.1	0.21	0.12	-0.09	0.08	70.11	0.09
A-6	60.14	59.8	60.06	0.34	0.08	-0.26	0.05	60	0.15
A-7	48.63	48.69	48.77	-0.06	-0.14	-0.08	-0.09	48.70	0.06
A-8	46.17	46.13	46.08	0.04	0.09	0.05	0.06	46.13	0.04
A-9	31.12	31.34	31.38	-0.22	-0.26	-0.04	-0.17	31.28	0.11
A-10	25.55	25.62	25.61	-0.07	-0.06	0.01	-0.04	25.59	0.03
B-1	47.74	47.63	47.58	0.11	0.16	0.05	0.11	47.65	0.07
B-2	30.79	30.8	30.84	-0.01	-0.05	-0.04	-0.03	30.81	0.02
B-3	26.07	26.01	26.02	0.06	0.05	-0.01	0.03	26.03	0.03
B-4	28.54	28.64	28.64	-0.10	-0.10	0.00	-0.07	28.61	0.05
B-5	46.74	47.08	47.09	-0.34	-0.35	-0.01	-0.23	46.97	0.16
B-6	49.04	48.9	48.73	0.14	0.31	0.17	0.21	48.89	0.13
B-7	29.23	29.81	29.32	-0.58	-0.09	0.49	-0.06	29.45	0.25
B-8	25.58	25.4	25.51	0.18	0.07	-0.11	0.05	25.50	0.07
B-9	25.92	26.1	25.82	-0.18	0.10	0.28	0.07	25.95	0.12
B-10	50.06	50.09	50.11	-0.03	-0.05	-0.02	-0.03	50.09	0.02

**Table A-1. Continued.**

<b>ALD Control</b>	<b>C1</b>	<b>C2</b>	<b>C3</b>	<b><math>\Delta 1v2</math></b>	<b><math>\Delta 1v3</math></b>	<b><math>\Delta 2v3</math></b>	<b><math>\Delta Avg</math></b>	<b>Mean</b>	<b>SD</b>
C-1	70.84	70.9	70.9	-0.06	-0.06	0.00	-0.04	70.88	0.03
C-2	62.32	62.43	62.59	-0.11	-0.27	-0.16	-0.18	62.45	0.11
C-3	51.25	51.39	51.41	-0.14	-0.16	-0.02	-0.11	51.35	0.07
C-4	30.78	30.74	30.77	0.04	0.01	-0.03	0.01	30.76	0.02
C-5	26.32	26.33	26.34	-0.01	-0.02	-0.01	-0.01	26.33	0.01
C-6	26.92	26.83	26.67	0.09	0.25	0.16	0.17	26.81	0.10
C-7	30.02	29.97	29.99	0.05	0.03	-0.02	0.02	29.99	0.02
C-8	43.5	43.52	43.6	-0.02	-0.10	-0.08	-0.07	43.54	0.04
C-9	47.07	46.77	46.83	0.30	0.24	-0.06	0.16	46.89	0.13
C-10	61.58	61.55	61.54	0.03	0.04	0.01	0.03	61.56	0.02

**Table A-2.** Summary of CBCT Measurements.

<b>V: CBCT</b>	<b>CBC1</b>	<b>CBC2</b>	<b>CBC3</b>	<b><math>\Delta 1v2</math></b>	<b><math>\Delta 1v3</math></b>	<b><math>\Delta 2v3</math></b>	<b><math>\Delta Avg</math></b>	<b>Mean</b>	<b>SD</b>
A-B	38.8	39.1	39	-0.30	-0.20	0.10	-0.13	38.97	0.15
B-C	39.6	39.9	39.8	-0.30	-0.20	0.10	-0.13	39.77	0.15
A-C	61.9	62	62.1	-0.10	-0.20	-0.10	-0.13	62	0.10
A-1	26.3	26.5	26.1	-0.20	0.20	0.40	0.13	26.3	0.20
A-2	30.2	30.1	30.2	0.10	0.00	-0.10	0.00	30.17	0.06
A-3	50.5	50.4	50.8	0.10	-0.30	-0.40	-0.20	50.57	0.21
A-4	60.4	60.7	60.9	-0.30	-0.50	-0.20	-0.33	60.67	0.25
A-5	69.1	69.5	69.3	-0.40	-0.20	0.20	-0.13	69.3	0.20
A-6	59	59.4	59.4	-0.40	-0.40	0.00	-0.27	59.27	0.23
A-7	47.9	47.8	48.2	0.10	-0.30	-0.40	-0.20	47.97	0.21
A-8	45.5	46	45.8	-0.50	-0.30	0.20	-0.20	45.77	0.25
A-9	30.7	31	31.1	-0.30	-0.40	-0.10	-0.27	30.93	0.21
A-10	25.4	25.6	25.4	-0.20	0.00	0.20	0.00	25.47	0.12
B-1	47	47.3	46.9	-0.30	0.10	0.40	0.07	47.07	0.21
B-2	30.7	30.8	30.8	-0.10	-0.10	0.00	-0.07	30.77	0.06
B-3	26.1	26	26.3	0.10	-0.20	-0.30	-0.13	26.13	0.15
B-4	28.9	28.9	28.8	0.00	0.10	0.10	0.07	28.87	0.06
B-5	47.4	47	47.1	0.40	0.30	-0.10	0.20	47.17	0.21
B-6	48.4	48.5	48.4	-0.10	0.00	0.10	0.00	48.43	0.06
B-7	29.7	29.5	29.4	0.20	0.30	0.10	0.20	29.53	0.15
B-8	25	25.2	25.1	-0.20	-0.10	0.10	-0.07	25.1	0.10
B-9	25.5	25.3	25.2	0.20	0.30	0.10	0.20	25.33	0.15
B-10	49.6	49.6	49.9	0.00	-0.30	-0.30	-0.20	49.7	0.17
C-1	70	70.2	70.1	-0.20	-0.10	0.10	-0.07	70.1	0.10
C-2	62.1	62.1	62.3	0.00	-0.20	-0.20	-0.13	62.17	0.12
C-3	51.1	51.3	51.2	-0.20	-0.10	0.10	-0.07	51.2	0.10
C-4	30.4	30.3	30.4	0.10	0.00	-0.10	0.00	30.37	0.06
C-5	26	26.1	26.1	-0.10	-0.10	0.00	-0.07	26.07	0.06

**Table A-2.** *Continued.*

<b>V: CBCT</b>	<b>CBC1</b>	<b>CBC2</b>	<b>CBC3</b>	<b><math>\Delta 1v2</math></b>	<b><math>\Delta 1v3</math></b>	<b><math>\Delta 2v3</math></b>	<b><math>\Delta Avg</math></b>	<b>Mean</b>	<b>SD</b>
C-6	26.2	26.6	26.7	-0.40	-0.50	-0.10	-0.33	26.5	0.26
C-7	29.7	29.7	29.9	0.00	-0.20	-0.20	-0.13	29.77	0.12
C-8	43.2	43.3	43.2	-0.10	0.00	0.10	0.00	43.23	0.06
C-9	46.5	46.4	46.5	0.10	0.00	-0.10	0.00	46.47	0.06
C-10	61.2	61.4	61.4	-0.20	-0.20	0.00	-0.13	61.33	0.12

## VITA

Dr. Nicholas Egbert was born in 1979. He received his Bachelors of Science in Medical Biology from the University of Utah in Salt Lake City, Utah in 2004. He then completed his Doctor of Dental Surgery from Creighton University, Omaha, Nebraska in 2004. He was accepted into the Advanced Prosthodontics Program at the University of Tennessee Health Science Center in 2008. Dr. Egbert is currently a third year resident, specializing in fixed and removable prosthodontics and surgical implant dentistry at UTHSC. He will be finishing his Master of Dental Science degree from the University of Tennessee. He is a current member of the American College of Prosthodontists (ACP) and eligible to challenge the board of examiners to become a Fellow of the ACP.